

# Lasers in oral implantology

Author Drs Ilay Maden & Zafer Kazak, Turkey

(BACKGROUND: ©EW; FEMALE DENTIST: ©FRANCK BOSTON)

## \_Introduction

Both lasers and implantology are considered to be the fashionable treatments of modern dentistry, and combining them seems to represent best practice from a number of perspectives. Implantology is one of the many dental indications for the use of lasers, and it is one from which patients can benefit significantly.

## \_The ideal scenario

Ideally, the soft tissue surrounding the implant should be prepared before starting an implant procedure. The vestibular sulcus depth and frenulum should be examined and prepared accordingly. This can also be performed during the second stage of surgery (Fig. 1). Different laser wavelengths can be used for this kind of surgery. Er:YAG lasers cause less pain, as they do not heat the tissue surface, unlike diode, Nd:YAG and CO<sub>2</sub> lasers, and the patient heals more quickly for the same reason.<sup>1,2</sup>

## \_Removal of granulation tissue

One of the most important uses of lasers in implantology is the removal of granulation tissue and disinfection of the surgical area after extraction.

Erbium lasers can be used for this purpose, especially if there was chronic infection before the extraction, regardless of whether implants or bone grafts are being placed (Fig. 2). It has even been suggested that implants can be placed at pre-infected sites, although the site has to be cleaned thoroughly.<sup>3</sup> Owing to significant differences in water content, the erbium laser can be used to only remove soft tissue by setting the parameters correctly (energy density, pulse duration, etc.). This is done without thermal side-effects on the bone,<sup>4</sup> and with greater comfort to the patient while disinfecting the surface,<sup>5</sup> since no force is applied, unlike with curettes. The non-contact or pseudo-contact procedure enables safe cleaning of very fragile bone that may even be in a bridge form if there is a fenestration.<sup>6</sup>

## Laser ablation

If the coronal part of the crest is too thin, and a plateau is desired, ablating the bone in order to achieve the desired thickness is advantageous, since, without a thermal effect, exposure of the implant neck can be avoided. This same safety benefit also applies when angulated implants are placed and distal neighbouring bone needs to be removed. Also, a laser can be used to make an indent to mark the location of the first drilling site because it will not slip and cause iatrogenic damage (especially helpful for novice implantologists). Lasers can also be used when the procedure involves an osteotomy sinus lift, obtaining a bone block or bone splitting (Figs. 3a & b).<sup>9,10</sup>

## Preparation of the implant bed

The Er:YAG laser can be used for the preparation of an implant bed in special cases, such as when the bone is very thin and soft. Thin contact tips can be used to remove the minimum amount of bone (Fig. 4), as they are thinner than pilot drills. Then the implant bed can be prepared using bone condensers. For other cases, it may also be beneficial to prepare the implant bed with a laser to achieve longer stability.<sup>11</sup> Ultimately, if scanner systems are combined with high-powered lasers for the purpose of shaping cavities of predetermined dimensions in the bone without the thermal side-effects of drills, it could be speculated that the results would improve even further: in addition to the disinfection of the site, the smear layer would be re-

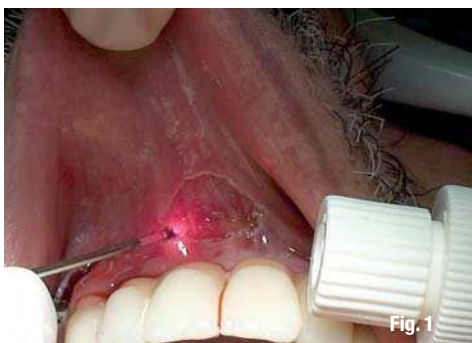

Fig. 1

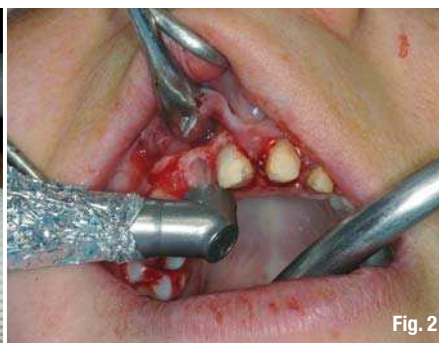

Fig. 2

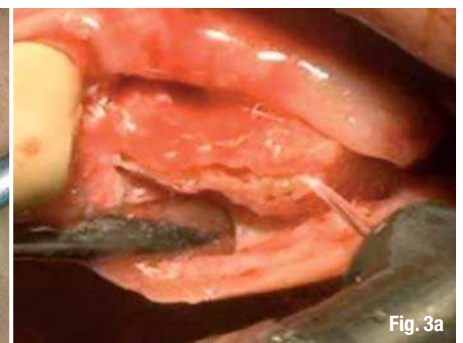


Fig. 3a

## Bio-modulation

After the removal of granulation tissue and superficial disinfection, a diode or Nd:YAG laser can be used for deep disinfection. The penetration of laser energy of these wavelengths in hydroxyapatite and absorption by bacterial pigments are advantageous in this case.<sup>7</sup> These wavelengths also have a bio-modulation effect, which aids healing, leading to less oedema and pain.<sup>8</sup> Bio-modulation is mostly effective during the initial healing phase, which is why it should be repeated every second day for the first few weeks.<sup>8</sup>

moved from the surface, activating osteoblastic activity.<sup>12</sup>

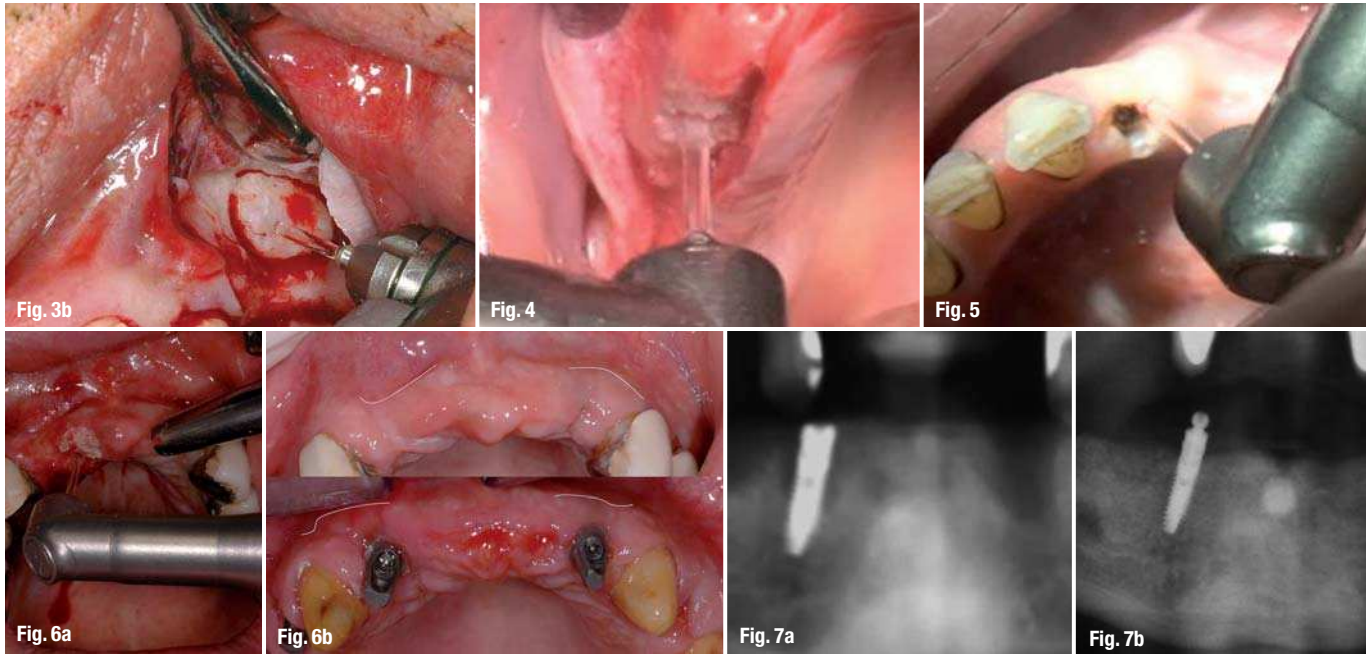
## Uncovering the implant

The most comfortable, patient-friendly use of the Er:YAG laser is during the second stage of implant placement: uncovering the implant (Fig. 5). Using a reduced water spray in order to decrease bleeding, it is possible to uncover the implant with diminished pain, even if bone is covering the implant. Using longer pulses causes haemostasis in the soft tissue, while shorter pulses enable the removal of bone without

**Fig. 1** Frenectomy with a diode laser after placement of full-arch implant-supported prostheses.

**Fig. 2** Cleaning and disinfecting the socket with an Er:YAG laser after extraction.

**Figs. 3a & b** Bone splitting (a). Sinus window preparation (b).



**Fig. 4**\_ Bone ablation for the implant bed.  
**Fig. 5**\_Uncovering the implant.  
**Figs. 6 a & b**\_De-epithelialisation of the crestal gingival to make a roll flap.  
**Figs. 7a & b**\_Peri-implantitis before treatment (a). After cleaning, disinfection and augmentation (b).

thermal side-effects. This is achieved without causing pain to the patient and without raising a flap. This is possible, of course, if there is sufficient attached gingiva and the crestal attached gingiva does not need to be replaced apically. When there is no harmful heating of the soft tissue, there is no retraction of tissue, so the impressions can be taken as soon as possible without delay. Another use is the de-epithelialisation of the crestal gingiva to make a roll flap in order to optimise vestibular soft-tissue thickness (Fig. 6).

**\_Peri-implantitis**

The most efficient use of the Er:YAG laser is in the treatment of peri-implantitis.<sup>14</sup> With Er:YAG, it is possible to clean the granulation tissue both on the bone surface and implant surface (Figs. 7a & b). This is done through decontamination of the site, which is the main purpose of peri-implantitis treatment.<sup>15,16</sup> Similar to the cleaning of the surgical area after extraction, it is possible to leave the highly fragile surrounding bone intact. The effect of the laser energy on the implant surface is dependent on the amount of energy density, power and possibly also pulse duration.<sup>17, 18</sup> The parameters should be chosen cautiously, however. Lowering the settings may make the procedure slower but safer for re-osseointegration. Non-surgical use of Er:YAG and diode lasers is also possible if the problem is not extensive.

The most prevalent reason for peri-implantitis appears to be poor occlusal load distribution, with either primary contacts or cantilever bridges in implant-supported prostheses. Good oral hygiene on the patient's part is mandatory. The position and design of prostheses that are difficult to manage may limit the

effectiveness of mechanical cleaning. Once the underlying reason has been determined and recurrence is prevented, the Er:YAG laser can help treat peri-implantitis. Finally, lasers are also used to enhance the aesthetics of implant-supported prostheses. Gingival levelling by crown lengthening and depigmentation are the most common procedures performed for this purpose.

**\_Conclusion**

From this range of laser applications, it is evident that the use of lasers in modern dentistry is only limited by the dentist's imagination. Ultimately, lasers are not miracle machines that can improve the quality of implantology overnight in cases in which the practitioner has limited knowledge and experience in implantology. However, they are indeed a major aid in doing what is needed, always enabling increased comfort, both for the operator and the patient. Education is certainly the key in implantology and laser dentistry in general.

*Editorial note: The complete list of references is available from the author.*

<b>_contact</b>	<b>laser</b>
<p><b>Dr İlay Maden PhD, MSc, BDS</b>                  Mühürdar Caddesi 69                  34710 Istanbul, Turkey                   ilaymaden@gmail.com</p>	